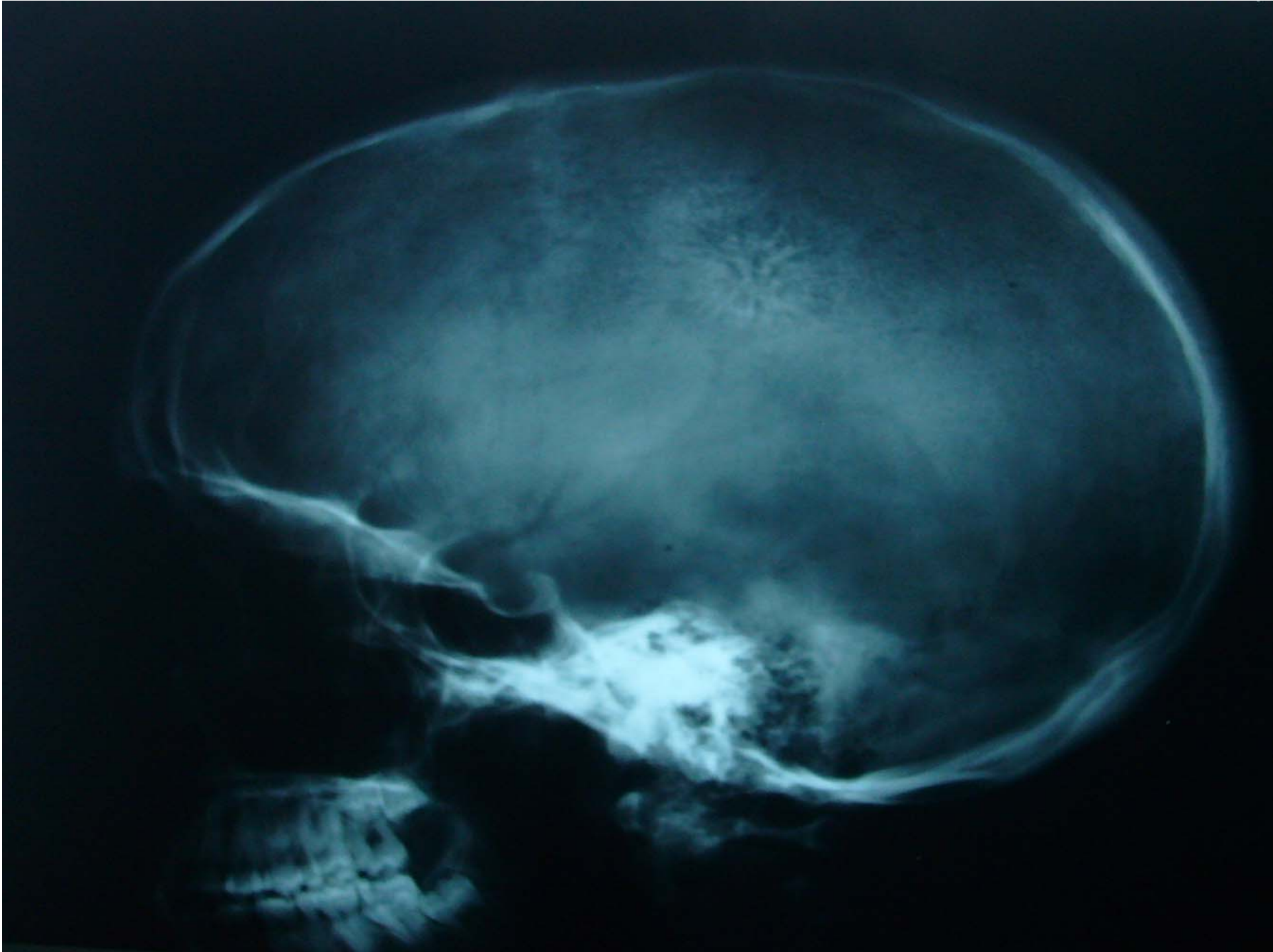

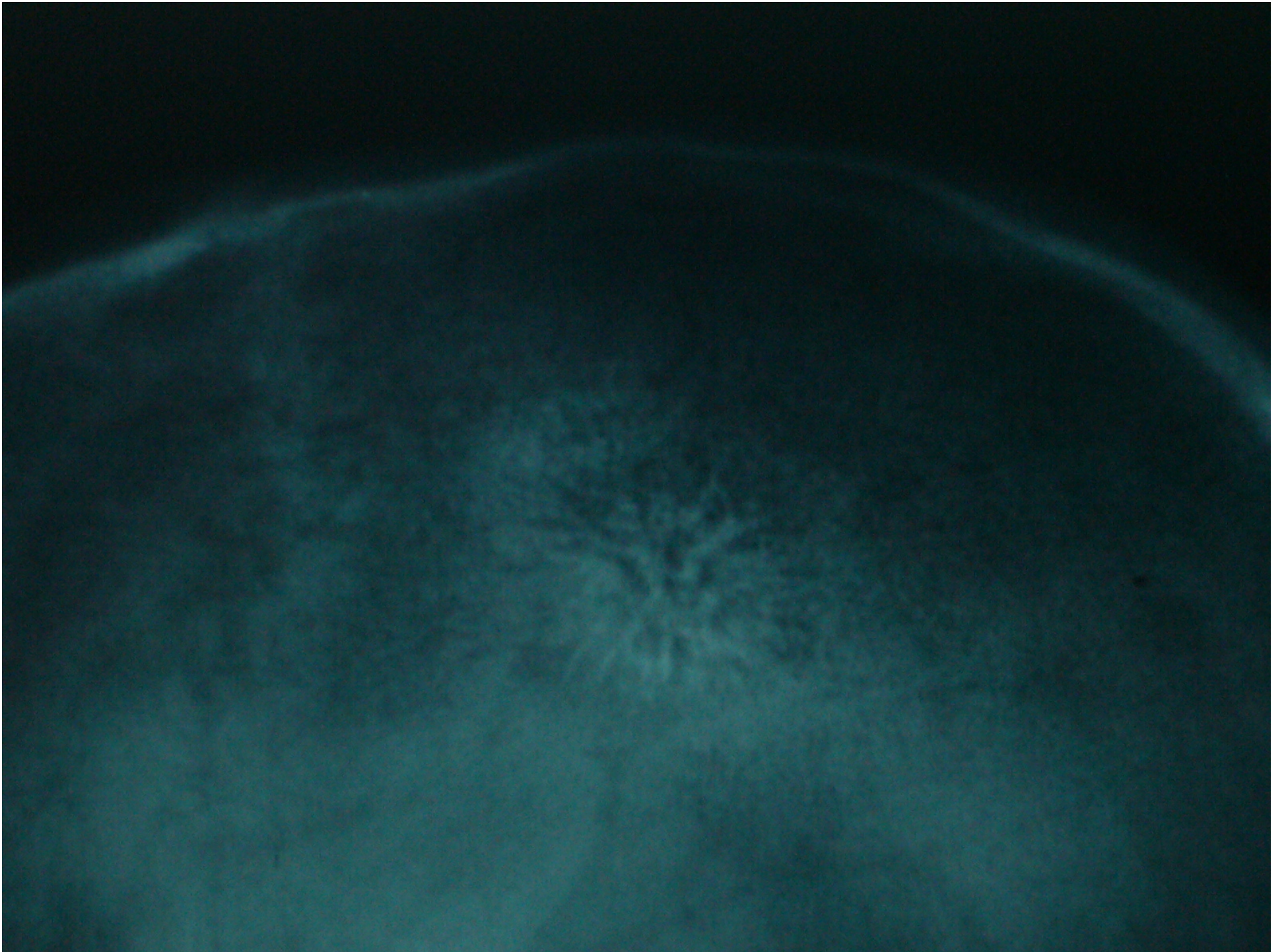
CAS CLÍNIC

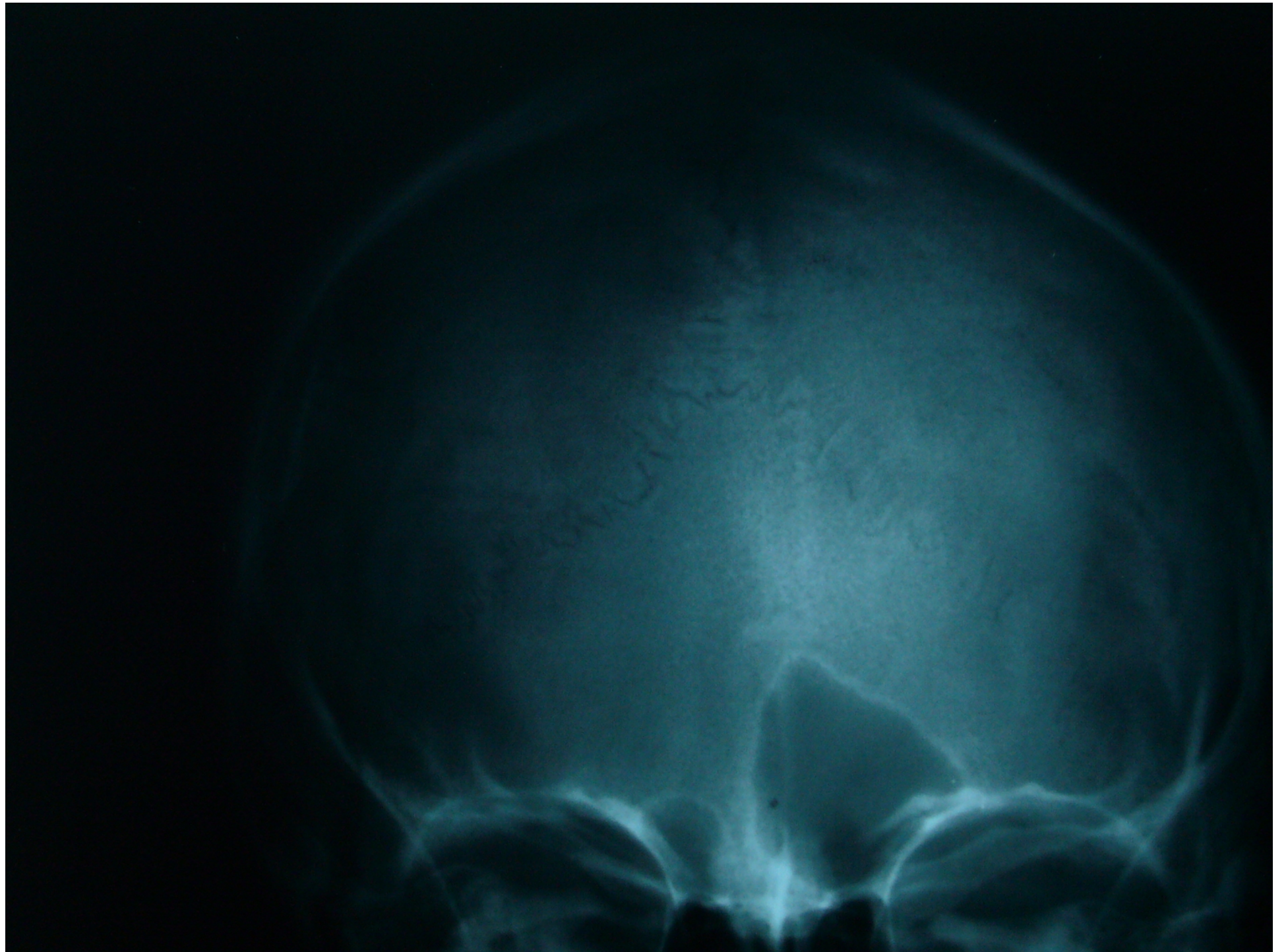CAP El Clot

Nena de 13 anys

Presentació brusca de mal de cap
Bultoma amb la zona parietal dreta





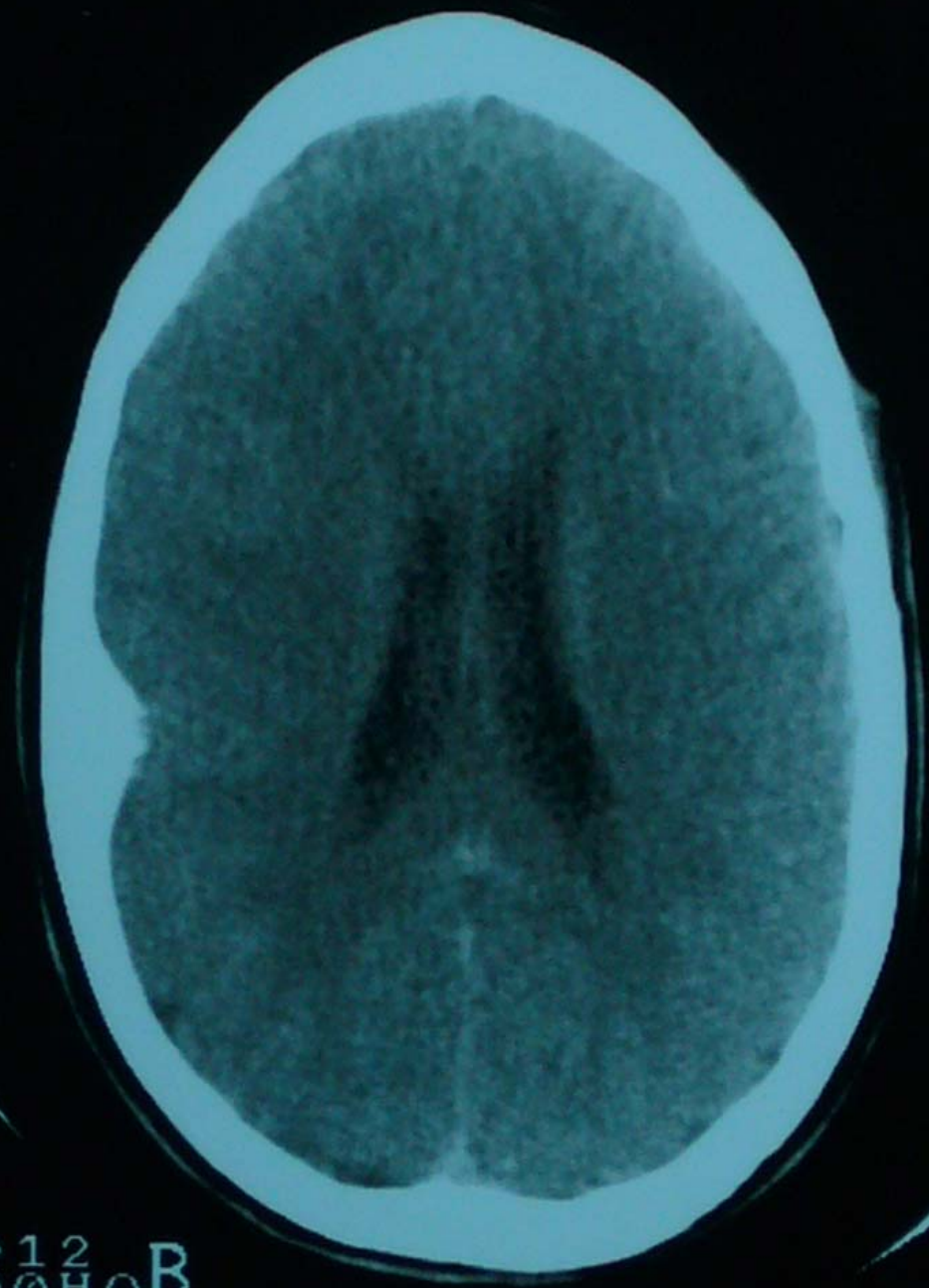


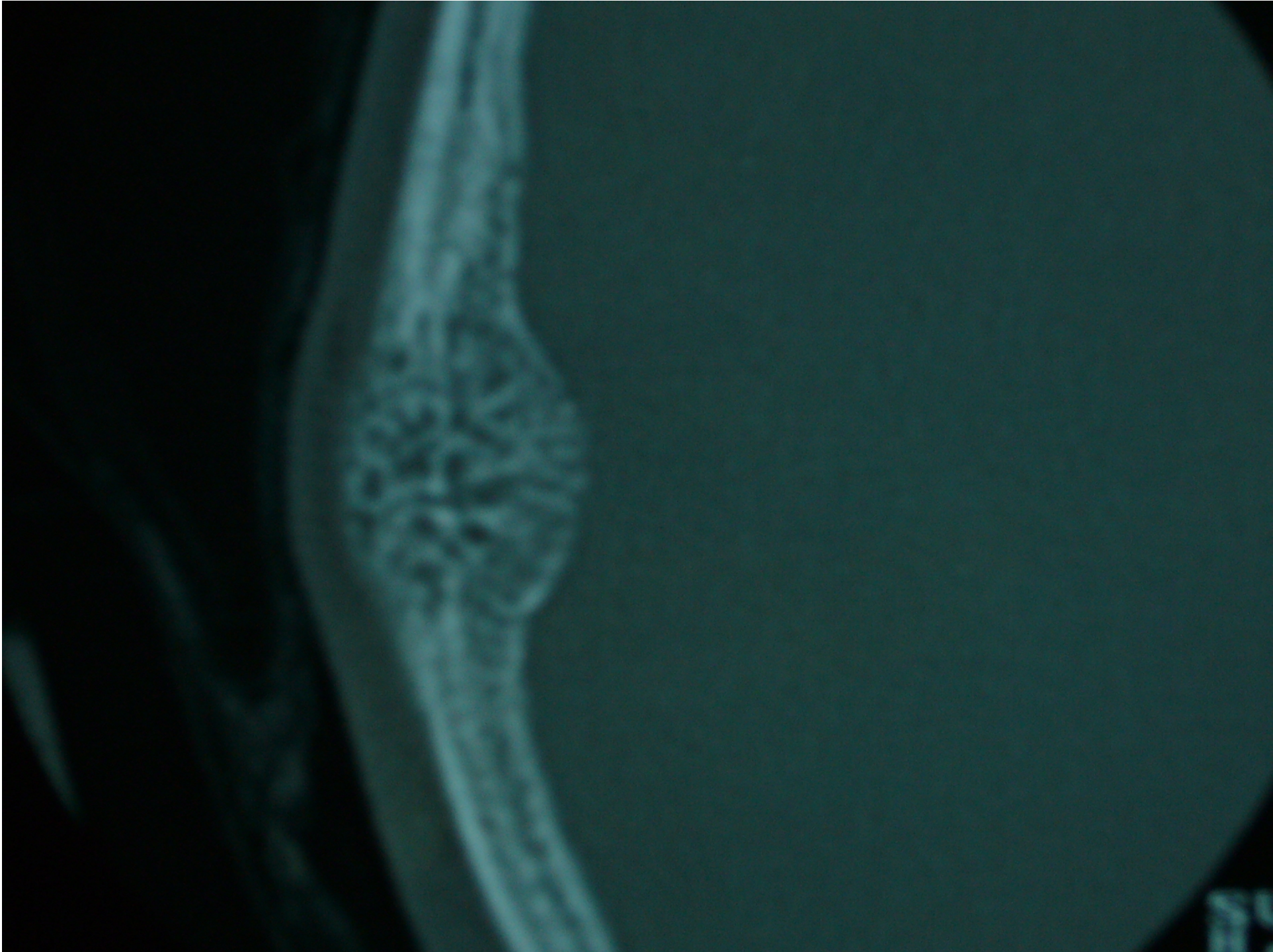
015:012
TCT600HQB

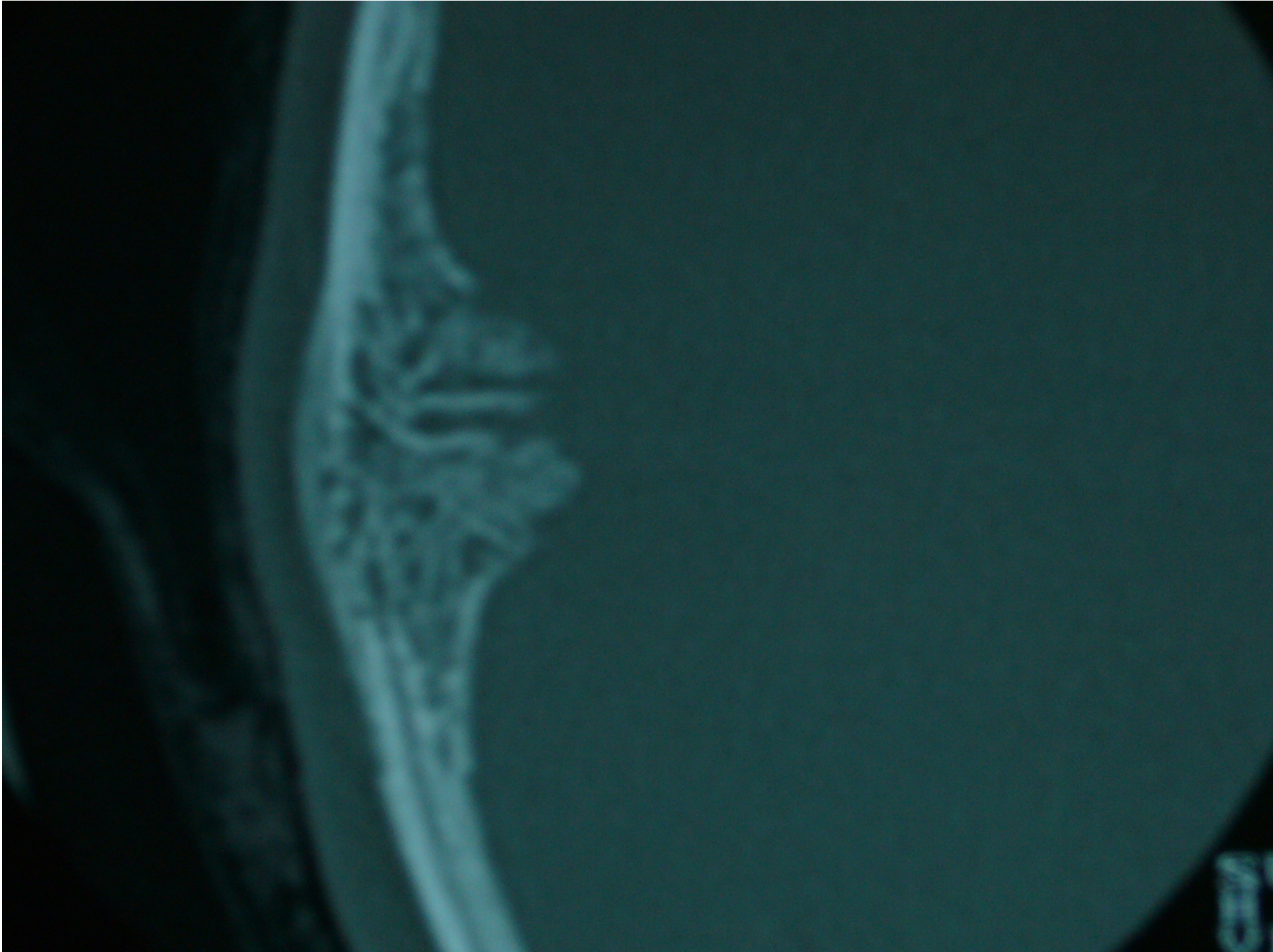
ST. JOAN DE

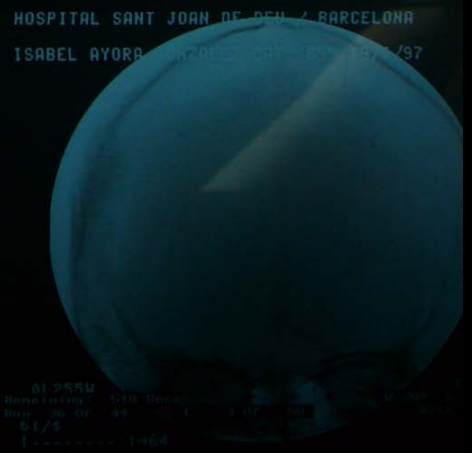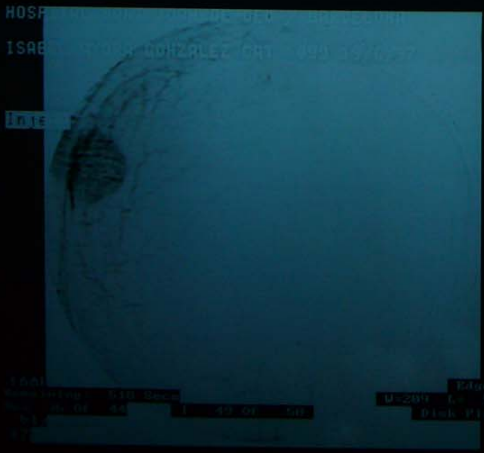
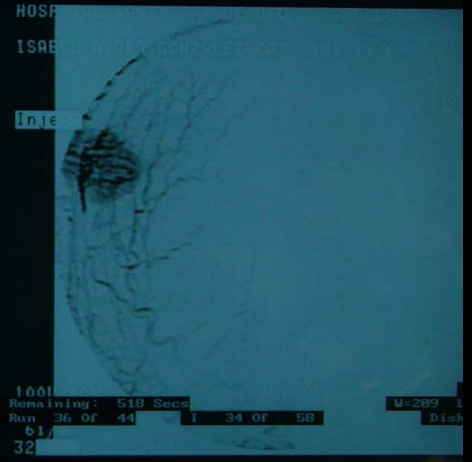
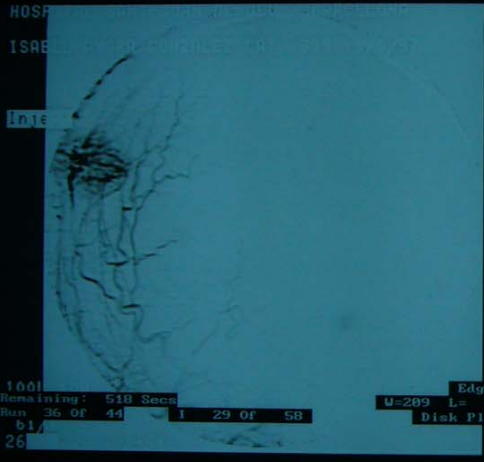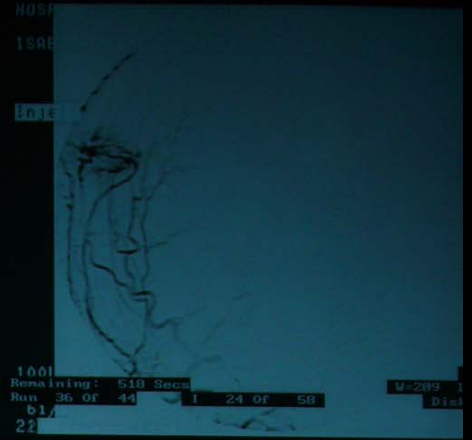
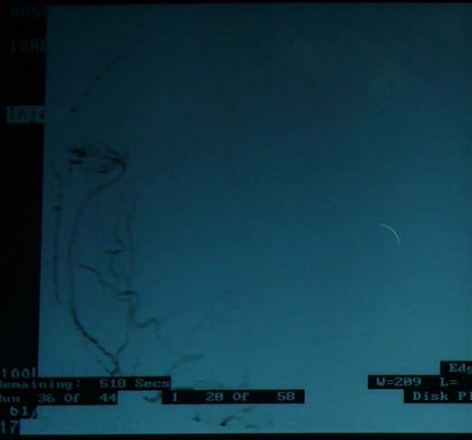3FCHS

R



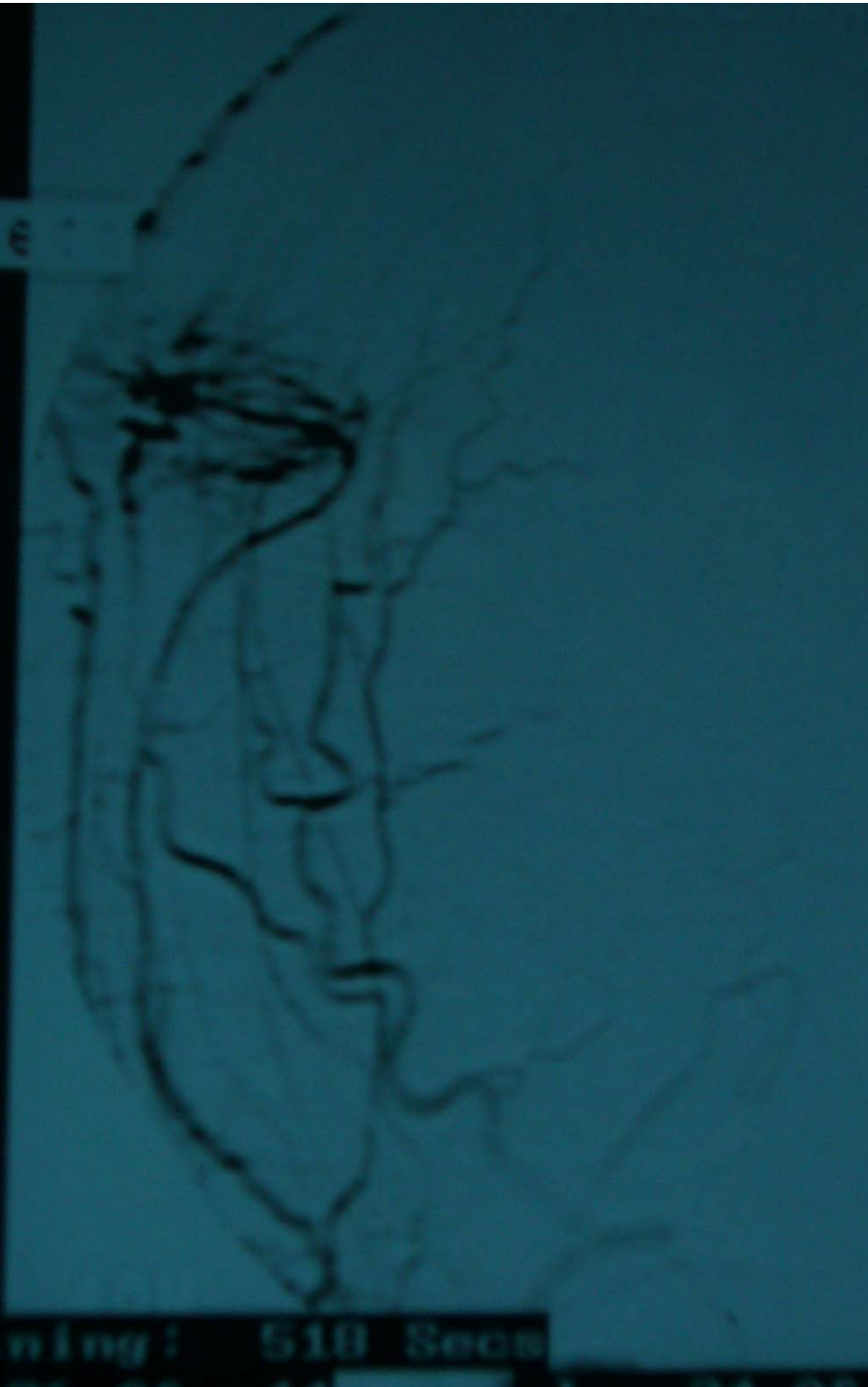


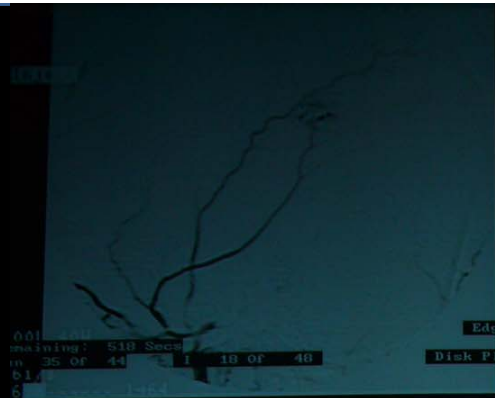


n. 16

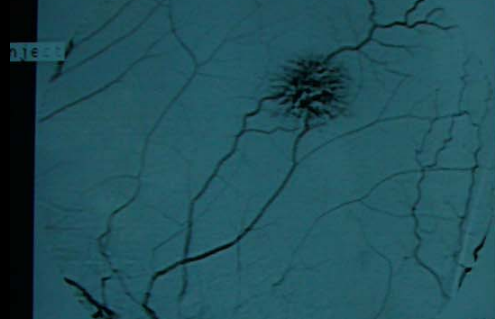001
Sampling: 510 Sec





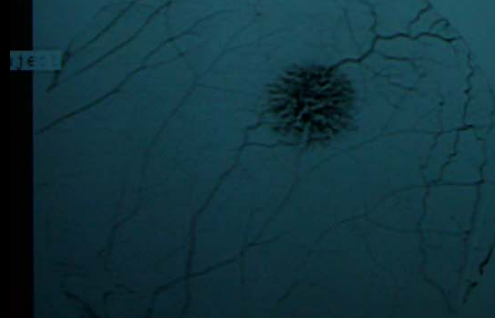001 100
Remaining: 518 Secs
Run 35 Of 44 1 18 Of 48
51
6

HOSPITAL SANTI JOAN DE DEU / BARCELONA
ISABEL AYORA GONZALEZ CAT. 899 19/6/97



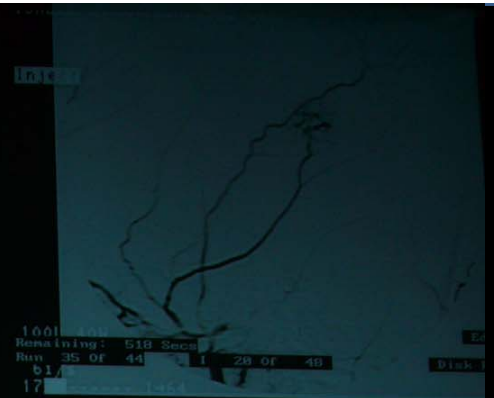001 100
Remaining: 518 Secs
Run 35 Of 44 1 28 Of 48
51
6

HOSPITAL SANTI JOAN DE DEU / BARCELONA
ISABEL AYORA GONZALEZ CAT. 899 19/6/97



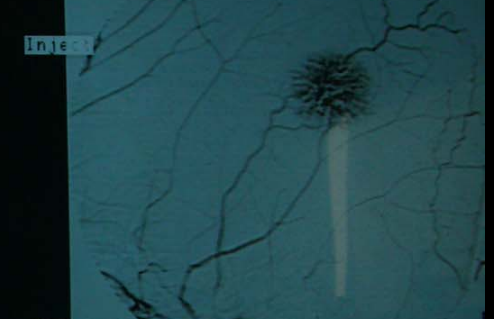001 100
Remaining: 518 Secs
Run 35 Of 44 1 35 Of 48
51
6

HOSPITAL SANTI JOAN DE DEU / BARCELONA
ISABEL AYORA GONZALEZ CAT. 899 19/6/97



1001 100
Remaining: 518 Secs
Run 35 Of 44 1 29 Of 48
51
17

HOSPITAL SANTI JOAN DE DEU / BARCELONA
ISABEL AYORA GONZALEZ CAT. 899 19/6/97



1001 100
Remaining: 518 Secs
Run 35 Of 44 1 31 Of 48
51
29

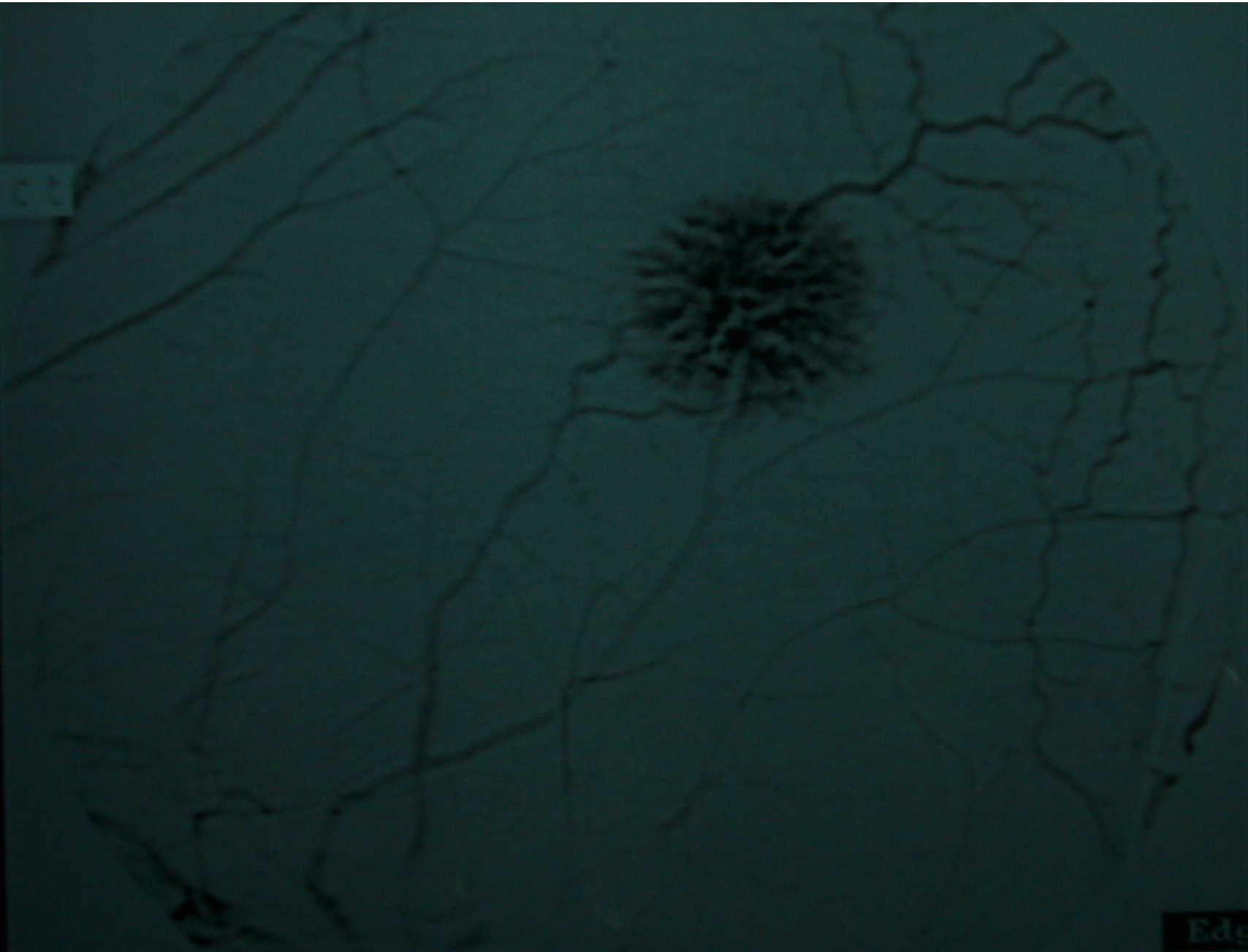
HOSPITAL SANTI JOAN DE DEU / BARCELONA
ISABEL AYORA GONZALEZ CAT. 899 19/6/97



1001 100
Remaining: 518 Secs
Run 35 Of 44 1 45 Of 48
51
44

HOSPITAL SANTI JOAN DE DEU / BARCELONA
ISABEL AYORA GONZALEZ CAT. 899 19/6/97

nject



Edge

001
Remaining: 518 Secs

35 of 44 1 35 of 48

Disk Play



